

## Appendicitis in strangulated femoral hernia: A case report.

Wael Rebai, Hassen Hentati, Amine Makni, Rachid Ksontini, Faouzi Chebbi, Fadhel Ftiriche, Mohamed Jouini, Montasser Kacem, Zoubeir Ben Safta.

Department of General Surgery, La Rabta Hospital, Jabbari, Tunis

*W.Rebai, H.Hentati, A.Makni, R.Ksontini, F.Chebbi, F.Ftiriche, M.Jouini, M.Kacem, Z.Ben Safta.*  
Appendicite aigue sur hernie crurale étranglée

*W.Rebai, H.Hentati, A.Makni, R.Ksontini, F.Chebbi, F.Ftiriche, M.Jouini, M.Kacem, Z.Ben Safta.*  
Appendicitis in strangulated femoral hernia: a case report.

LA TUNISIE MEDICALE - 2010 ; Vol 88 (n°03) : 193 - 195

LA TUNISIE MEDICALE - 2010 ; Vol 88 (n°03) : 193 - 195

### R É S U M É

**Prérequis:** La présence de l'appendice dans le sac d'une hernie crurale, appelée encore la hernie de De Garengéot, est une situation rare, découverte fortuitement au cours de la cure de hernie. La découverte d'une appendicite aigue dans le sac d'une hernie crurale étranglée est encore plus rare.

**But:** Rapporter une nouvelle observation

**Observation:** Nous rapportons le cas d'une patiente âgée de 45 ans, hospitalisée en urgence pour une tuméfaction douloureuse de l'aîne droite, située au dessous de la ligne de Malgaine, irréductible et non impulsive à la toux, sans troubles du transit. Le diagnostic de hernie crurale étranglée était retenu. La patiente était opérée en urgence par une incision inguinale droite. L'ouverture du sac avait trouvé un appendice phlegmoneux associé à un épanchement séro-hématique. Il a été réalisé une appendicectomie, une résection du sac herniaire associées à une pariétorrhaphie selon la technique de Mac Vay. Les suites opératoires étaient simples.

**Conclusion:** Les chirurgiens devraient être avertis de cette forme atypique et rare aussi bien de l'appendicite aigue que de la hernie crurale.

### Mots-clés

Appendicite - Appendicectomie - Hernie crurale - Hernie de De Garengéot.

### S U M M A R Y

**Background:** Herniation of the appendix into a femoral hernia – also called De Garengéot hernia - is a rare but well-recognized entity. It is typically discovered incidentally during hernia repair. Acute appendicitis in a strangulated femoral hernia is even more uncommon.

**Aim:** Report a new case

**Case:** We report on a patient admitted for a painful groin mass. She underwent emergency surgery. Exploration identified acute appendicitis in a strangulated femoral hernia sac.

**Management:** Appendectomy associated with Mac Vay's herniorrhaphy were performed. The outcome was uneventful.

**Conclusion:** Surgeons should be aware of the existence of this infrequent and atypical presentation of appendicitis and femoral hernia.

### Key - words

Appendicitis - Appendectomy - Femoral hernia - De Garengéot Hernia.

Location of the vermiform appendix within an abdominal-wall hernia is variously reported as occurring in less than 1 per cent of all abdominal-wall hernias [1]. Acute appendicitis in a femoral hernia sac is even more infrequent [2]. De Garegeot is credited with the first case report in 1731 [3,4]. Due to the infrequent occurrence, De Garegeot hernia has been sparingly reported as case reports and small case series [2].

We report on a patient with an acute appendicitis in a strangulated femoral hernia sac presenting with a painful groin mass.

---

### CASE REPORT

---

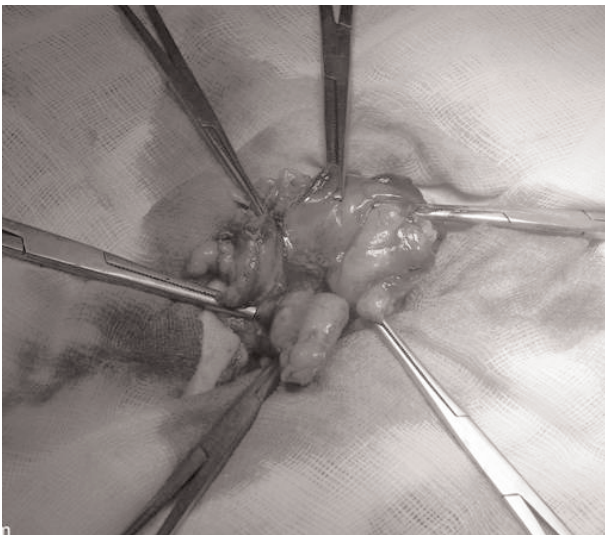
A 45-year-old woman was admitted for the sudden appearance of a painful right groin mass. There was no fever, nausea, vomiting, diarrhea or constipation.

On physical examination, a right groin nonreducible and tender mass was found in the femoral region, which did not convey the cough thrust. Abdominal examination ended with strictly normal findings. The preoperative diagnosis was strangulated femoral hernia.

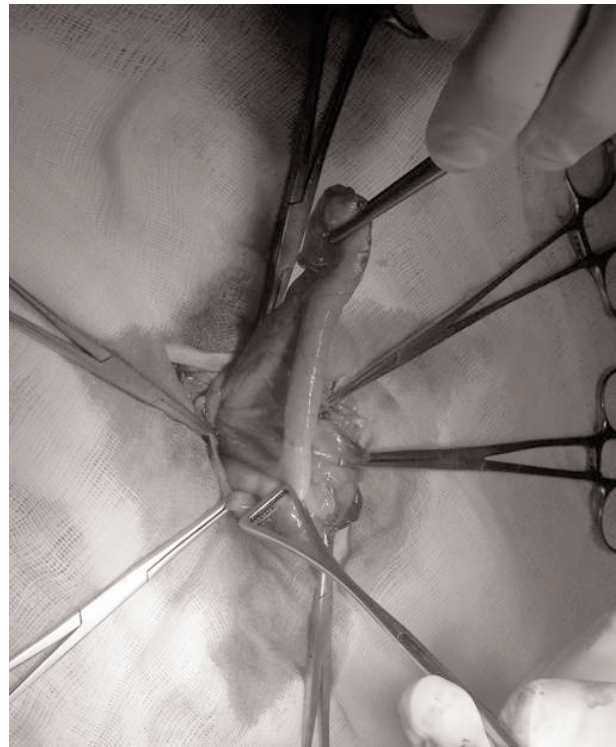The patient underwent immediate surgery through a right inguinal incision. Surgical exploration found a strangulated femoral hernia sac containing inflamed appendix (Figure 1). The appendix was totally in the hernia sac with its mesentery (Figure 2). We proceeded with appendectomy, hernia sac resection and Mac Vay's herniorrhaphy.

The outcome was uneventful. The patient was discharged on the second postoperative day without any complication.

**Figure 1:** Inflamed appendix within a strangulated femoral hernia sac.



**Figure 2 :** L'appendice et son méso dans le sac herniaire.



---

### DISCUSSION

---

Femoral hernias are more common in women ages 30 to 60 years. A femoral hernia lies in the femoral canal medially to the femoral vein and posteriorly to the line of the inguinal ligament [5]. The hernial sac may contain preperitoneal fat, omentum, small bowel or colon and, rarely, the appendix, reported to occur in 0.8% of femoral hernias [6]. Inflammation of the appendix within the femoral canal is extremely rare. In patients with acute appendicitis, 0.13% has been reported to occur in various external hernia sacs [5]. De Garegeot first reported an appendix in a femoral hernia sac in 1731[1-3]. In 1735, Amyand carried out the first recorded appendectomy by removing a perforated appendix in an inguinal hernia.

Controversy reigns regarding the pathogenesis of De Garegeot hernia [2]. It has also been speculated that a very large cecum, extending into the pelvis, can give rise to the appendix entering a hernial sac [6]. The inflammation of the appendix in the hernia sac is usually caused by extraluminal obstruction due to the pressure of the hernia neck rather than intraluminal obstruction of the appendix [4,6,7].

The diagnosis of acute appendicitis occurring within a femoral hernia is rarely made preoperatively [1]. The clinical signs and symptoms of De Garegeot hernia are those of incarcerated femoral or inguinal hernia and include vague abdominal pain and tenderness and an erythematous groin lump [2]. The tight neck serves to wall off the disease and thus often prevents the generalised abdominal signs of appendicitis. Upon rupture of

the organ, peritonitis does not result [2,3]. Sometimes though, there are prodrome symptoms that are typical of appendicitis, such as periumbilical or epigastric pain localizing to the right lower quadrant or the right groin [8].

CT scan of the groin has been established to be highly sensitive recently [5,9], but an evident incarcerated femoral hernia leaves little room for radiological investigations [2,8]. In fact, many of the reported patients underwent emergency surgery without preoperative CT scan because of suspected strangulated hernias [10], as in our patient.

The treatment of choice of this disease entity is emergency surgery [2] and consists in simultaneous appendectomy through the hernia incision and primary hernia repair [2,6,8]. Generally, herniorrhaphy is preferred to prosthetic hernia repair due to the risk of infection [2,10]. However, some authors have mentioned mesh repair even in the presence of an inflamed appendix with no postoperative infection [2,7]. In our patient, we preferred suture to mesh repair. In case of groin hernia abscess caused by perforated appendix, some authors prone incision and drainage with delayed appendectomy and hernia repair [6].

Wound infection is the most common complication of the De Garengeot hernia repair with a rate reaching 29%. Some cases of necrotizing fasciitis and even death have been reported [3,6,7], probably related to the delay in diagnosis and the older age of the patients.

---

### CONCLUSION

---

Acute appendicitis in strangulated femoral hernia is a rare entity. The diagnosis is usually made per operatively. Appendectomy with herniorrhaphy is the treatment of choice.

### Références

1. Cutolo LC, Wasserman I, Pinck RL, Mainzer RA. Acute suppurative appendicitis occurring within a femoral hernia: report of a case. *Dis Colon Rectum* 1978;21:203-4.
2. Sharma H, Jha PK, Shekhawat NS, Memon B, Memon MA. De Garengeot hernia: an analysis of our experience. *Hernia*.2007;11:235-8.
3. Voitek AJ, MacFarlane JK, Estrada RL. Ruptured appendicitis in femoral hernias: report of two cases and review of the literature. *Ann Surg*1974; 179:24-6.
4. El Mansari O, Sakit F, Janati MI. Acute appendicitis on crural hernia. *Presse Med.* 2002 13;31:1129-30.
5. Fukukura Y, Chang SD. (2005) Acute appendicitis within a femoral hernia: multidetector CT findings. *Abdom Imaging.* 2005;30:620-2.
6. Nguyen ET, Komenaka IK. Strangulated femoral hernia containing a perforated appendix. *Can J Surg* 2004;47:68-9.
7. Barbaros U, Asoglu O, Seven R, Kalayci M. Appendicitis in incarcerated femoral hernia. *Hernia.* 2004;8:281-2.
8. Salemis NS, Nisotakis K, Nazos K, Stavrinou P, Tsohataridis E. Perforated appendix and periappendicular abscess within an inguinal hernia. *Hernia.* 2006;10:528-30.
9. Luchs JS, Halpern D, Katz DS. Amyand's hernia: prospective CT diagnosis. *J Comput Assist Tomogr.* 2000;24:884-6.
10. Gillion JF, Bornet G, Hamrouni A, Jullès MC, Convard JP. (2007) Amyand and de Garengeot' hernias. *Hernia*2007; 11:289-290.