

## Chondrosarcoma of sinonasal cavity: A case report and brief literature review

Salima Kharrat, Samia Sahtout, Sahbi Tababi, Safa Temimi, Meriem Ben Miled, Wafa Abid, Rim Zainine, Kais Nouira\*, Emna Menif\*, Najeh Beltaief, Ghazi Besbes.

*Service ORL hôpital la Rabta, Tunis (Tunisie).*

*\*Service de Radiologie hôpital la Rabta, Tunis (Tunisie).*

*S. Kharrat, S. Sahtout, S. Tababi, S. Temimi, M. Ben Miled, W. Abid, R. Zainine, K. Nouira, E. Menif, N. Beltaief, G. Besbes.*

*S. Kharrat, S. Sahtout, S. Tababi, S. Temimi, M. Ben Miled, W. Abid, R. Zainine, K. Nouira, E. Menif, N. Beltaief, G. Besbes.*

Agressive signal Chondrosarcoma: A propos d'un cas

Chondrosarcoma of sinonasal cavity: a case report and brief literature review

LA TUNISIE MEDICALE - 2010 ; Vol 88 (n°02) : 113 - 115

LA TUNISIE MEDICALE - 2010 ; Vol 88 (n°02) : 113 - 115

### R É S U M É

**Prérequis :** Les chondrosarcomes sont des tumeurs malignes d'origine cartilagineuse à évolution lente. Ces tumeurs peuvent siéger au niveau de la tête et du cou particulièrement au niveau du massif facial avec atteinte préférentielle de la mandibule et du maxillaire. La localisation naso-sinusienne est très rare.

**Observation :** Nous rapportons le cas d'un homme âgé de 43 ans chez qui on découvre accidentellement un chondrosarcome naso-ethmoïdo-maxillaire. Le patient a été opéré par voie endonasale sous guidage endoscopique. Une radiothérapie complémentaire a été réalisée avec une bonne évolution et une absence de récurrence à 5 ans de recul.

**Conclusion :** La chirurgie constitue le traitement de choix des chondrosarcomes. La chirurgie endonasale peut garantir une résection tumorale complète dans des cas bien sélectionnés.

### S U M M A R Y

**Background :** Chondrosarcomas are slow-growing malignant tumors that usually arise from cartilaginous structures. It may occur in the head and neck region with a predilection for the maxillofacial skeleton, where it has been reported to occur particularly in the mandible and maxilla. Chondrosarcoma of the sinonasal tract is very rare.

**Case :** We present the case of a 43-year-old man presenting with an incidental finding of a chondrosarcoma of the maxillary and ethmoid sinus with nasal extension. The tumor was completely resected using a transnasal endoscopic approach. Treatment has followed by a radiation therapy and the patient was considered free of disease at her 5 years follow-up.

**Conclusion:** Surgery is the mainstay treatment of chondrosarcomas. In selected patients, complete resection can be achieved using transnasal endoscopic approach.

### M o t s - c l é s

Chondrosarcoma - sinus - Nasal cavity.

### Key - w o r d s

Chondrosarcome - Sinus - Cavité nasale.

Chondrosarcoma is a rare, slow-growing tumor that usually arises from cartilaginous structures.

Chondrosarcomas make up only 10–20% of malignant primary bone tumors and are usually found in the pelvis, long bones, and ribs, with only 5 - 10% located in the head and neck, most commonly in the larynx, maxilla, mandible, and skull base. Chondrosarcoma of the sinonasal tract is very rare.

---

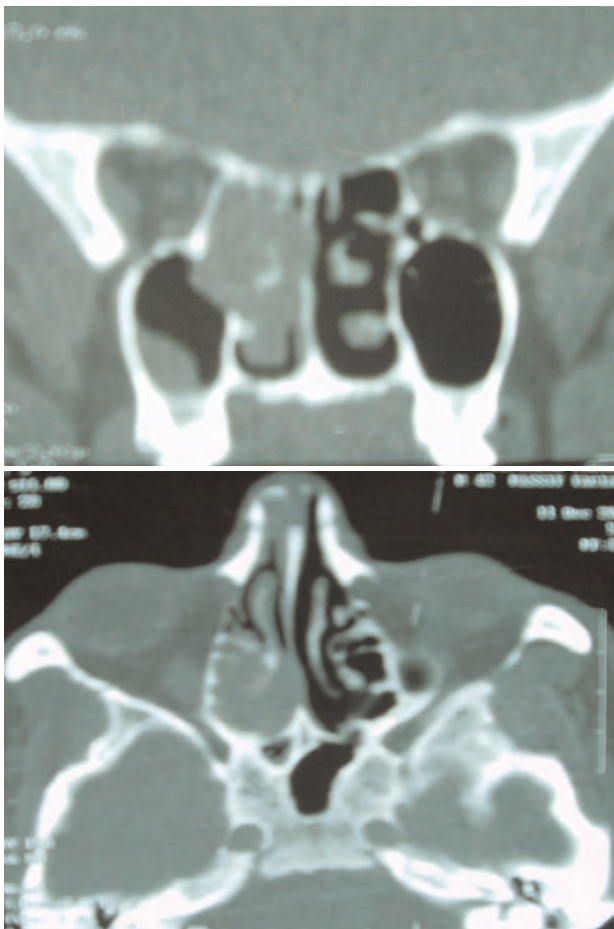
### CASE REPORT

---

A 43-year-old man with no significant medical history presented a 12-month history of right-sided sinus congestion associated with clear rhinorrhea without epistaxis. Nasal endoscopic exam showed polypoid mass of the right nasal cavity. The patient was referred to radiology and a CT of the sinuses was obtained.

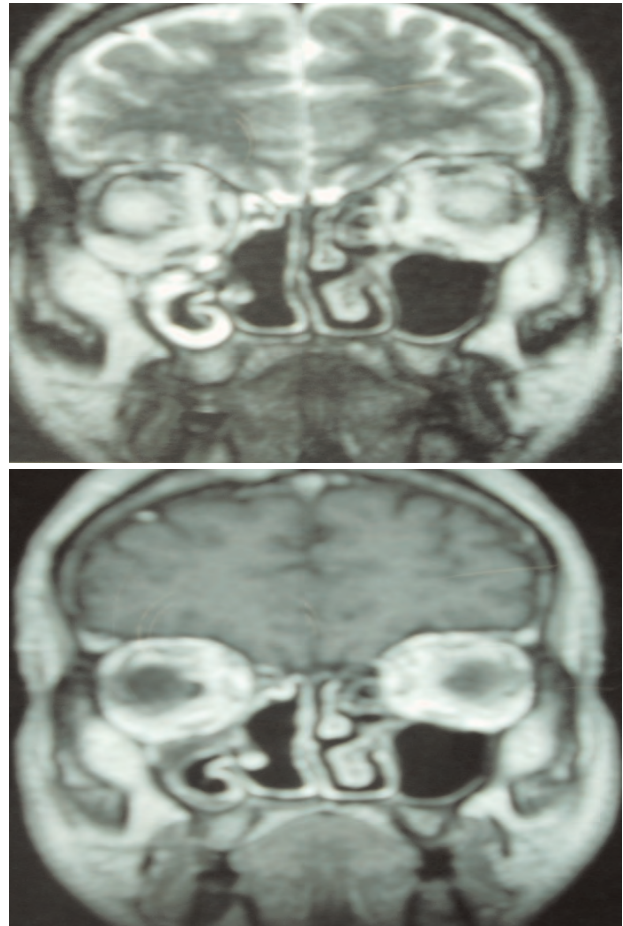
Unenhanced computed tomography (CT) examination of the sinuses (fig 1 and 2) showed an expansive, polypoid soft tissue mass arising in the right nasal cavity, ethmoid cells and right maxillary sinus. There was no bone erosion of the skull base and no extension into the intracranial space.

**Figure 1 & 2 :** coronal and axial CT scan showing tissue mass arising in the right nasal cavity, ethmoid cells and right maxillary sinus



ethmoidectomy, resection of the lateral wall of nasal cavity and middle turbinectomy. The final pathological diagnosis was grade 3 chondrosarcoma. Treatment has followed by a radiation therapy (64 Gy). MRI was performed at the end of treatment and 3 years post operatively showing no recurrence (fig 3 and 4). The patient was considered free of disease at her 5 years follow-up.

**Figure 3 & 4 :** MRI T2 and T1 with gadolinium showing the vacuity of sinonsal tract with no recurrence of the tumor.



---

### DISCUSSION

---

Chondrosarcoma comprises approximately 8% of primary bone tumors overall. Less than 10% of chondrosarcomas are found in the head and neck region (1, 2). Originally identified in the literature by Lichtenstein and Bernstein in 1959 as a biphasic tumor comprised of spindle cell mesenchyme interspersed with areas of chondroid differentiation (1).

The tumor is more commonly seen in a younger subset of the population than the conventional chondrosarcoma, with fewer

than 20% of the 111 cases reviewed by Nakashima, arising in patients over 40 years of age (2). A unique feature of this tumor is its ability to arise in either bone or soft tissue, with a predilection for skeletal origin of approximately two-to-one. Common skeletal sites in order of occurrence include the craniofacial bones (particularly the jaws) and spine while the meninges and lower extremity each comprise over a quarter of the extraskeletal cases (3, 4). Chondrosarcoma of the sinonasal tract is very rare (5, 8, 9). Patients may present with symptoms of nasal obstruction or discharge, chronic sinusitis, epistaxis, facial asymmetry, headache, restricted ocular movement, diplopia, proptosis, facial pain, dentition changes, or nasal/aural fullness (2-5).

Chondrosarcomas are graded on a 1 to 3 scale corresponding to a histological classification from a well-differentiated to undifferentiated tumor, based on the rate of mitoses, cellularity, and nuclear size (6). Grade 1 chondrosarcomas have abundant chondroid matrix, clusters of chondrocytes with normal or slightly enlarged nuclei, rare nucleoli, absent mitoses, and occasional binucleation. Grade 2 chondrosarcomas appear to have less chondroid matrix and more chondrocytes than grade 1 tumors, presence of rare mitoses, slightly enlarged vesicular hyperchromatic nuclei, and multinucleation. Grade 3 chondrosarcomas display a myxoid matrix with irregularly shaped chondrocytes and increased cellularity, nuclear pleomorphism, and mitoses compared with the lowgrade chondrosarcomas (6).

The clinical and radiologic differential diagnosis includes chondroma, meningioma, osteomas, osteosarcomas, fibrous lesions, and chordoma (3, 7).

Diagnostic modalities by both CT and MRI are essential in preoperative planning. On CT, chondrosarcomas typically appear as a hypodense matrix with scattered small rings

forming calcifications and bone erosion. MRI typically demonstrates a low-intensity T1 imaging, high-intensity T2 imaging, and intermediate enhancement with T1 with gadolinium (5, 8, 9, 10). Surgical excision with wide surgical margins is the mainstay treatment. Surgical extirpation can be completed by using a variety of approaches such as lateral rhinotomy with or without medial maxillectomy, the transpalatal approach, Le Fort I osteotomy, and transnasal endoscopic approaches (11, 12, 13). The endoscopic approach avoids facial and oral incisions and produces the least morbidity.

Its use is limited by the access provided by the nasal cavity and paranasal sinuses, the vascularity, size, and extension of the tumor, and the availability of the special instrumentation (14).

Similar to the treatment of other sarcomas, postoperative radiation therapy has been standard practice for mesenchymal chondrosarcoma.

Regional and distant metastasis are rare. The clinical course can be extremely protracted with relapses having occurred greater than 20 years after treatment of the primary tumor, making long-term follow-up a must in these patients (15).

In the most recent review of the literature on chondrosarcoma of the head and neck, 5-year survival rates for all histologic grades ranged from 54% to 81% (7, 9, 14).

---

## CONCLUSION

---

This case report shows the feasibility of using endoscopic techniques to aid in the resection of selected malignant tumors of the nose. Although we do not advocate the use of endoscopic approaches for all malignant tumors, tumors that are limited in size and fully visualized by endoscopic techniques are amenable to endoscopic resection.

## RÉFÉRENCES

1. Lichtenstein L, Bernstein D. Unusual benign and malignant chondroid tumors of bone. A survey of some mesenchymal cartilage tumors and malignant chondroblastic tumors, including a few multicentric ones, as well as many atypical benign chondroblastomas and chondromyxoid fibromas. *Cancer* 1959; 12: 1142-57.
2. Nakashima Y, Unni KK, Shives TC, Sweet RG, Dahlin DC. Mesenchymal chondrosarcoma of bone and soft tissue. A review of 111 cases. *Cancer* 1986; 57: 2444-53.
3. Ly J. Mesenchymal chondrosarcoma of the maxilla. *AJR* 2002; 179: 1077-8.
4. Knott PD, Gannon FH, Thompson LDR. Mesenchymal chondrosarcoma of the sinonasal tract: a clinicopathological study of 13 cases with a review of the literature. *Laryngoscope* 2003; 113: 783-90.
5. Ariyoshi Y, Shimahara M. Mesenchymal chondrosarcoma of the maxilla: report of a case. *J Oral Maxillofac Surg* 1999; 57: 733-7.
6. Huvos AG, Rosen G, Dabska M, Marcove RC. Mesenchymal chondrosarcoma. A clinicopathologic analysis of 35 patients with emphasis on treatment. *Cancer* 1983; 51: 1230-7.
7. Dahlin DC, Henderson ED. Mesenchymal chondrosarcoma: further observations in a new entity. *Cancer* 1962; 15: 410-7.
8. Takahashi K, Sato K, Kanazawa H, Wang XL, Kimura T. Mesenchymal chondrosarcoma of the jaw, report of a case and review of 41 cases in the literature. *Head Neck* 1993; 15: 459-64.
9. Aziz SR, Miremadi AR, McCab JC. Mesenchymal chondrosarcoma of the maxilla with diffuse metastasis: case report and literature review. *J Oral Maxillofac Surg* 2002; 60: 931-5.
10. Shinaver CN, Mafee MF, Choi KH. MRI of mesenchymal chondrosarcoma of the orbit: case report and review of the literature. *Neuroradiology* 1997; 39: 296-301.
11. Shapeero LG, Vanel D, Couanet D, Contesso G, Ackerman LV. Extraskeletal mesenchymal chondrosarcoma. *Radiology* 1993; 186: 819-26.
12. Rassekh CH, Nuss DW, Kapadia SB, Curtin HD, Weissman JL, Janecka IP. Chondrosarcoma of the nasal septum: skull base imaging and clinicopathologic correlation. *Otolaryngol Head Neck Surg* 1996; 115: 29-37.
13. Ruark DS, Schlehaider UK, Shah JP. Chondrosarcomas of the head and neck. *World J Surg* 1992; 16: 1010-6.
14. Ricardo L, Carrau, MD, FACS, Barlas Aydogan, MD, and Jennifer L. Hunt, MD. Chondrosarcoma of the sphenoid sinus resected by an Endoscopic Approach. *American Journal of Otolaryngology*, 2004; 25 : 274-277.
15. Phillip K. Pellitteri a, Alfio Ferlito b, Johannes J. Fagan c, Carlos Suarez de, Kenneth O. Devaney f, Alessandra Rinaldo. Mesenchymal chondrosarcoma of the head and neck. *Oral Oncology* 2007; 43: 970-975.